

DIAGNOSTIC VALUE OF ULTRASOUND GUIDED TRANSTHORACIC FINE NEEDLE ASPIRATION CYTOLOGY IN BRONCHOGENIC CARCINOMA

Dilip S Taviad, Srilaxmi P Hiriyur, Viral P Patel, Pawan C Nikhra, Avinash B Panchal

Department of Pathology, Medical College, Baroda, Gujarat, India

Correspondence to: Dilip S Taviad (drdiliptaviad.2013@yahoo.com)

DOI: 10.5455/ijmsph.2014.090620142

Received Date: 25.05.2014

Accepted Date: 09.06.2014

ABSTRACT

Background: Transthoracic FNAC is regarded as the most effective of the cytological methods for diagnosing lung cancer, in particular peripherally-located lesions. Notably, it demonstrates high accuracy in distinguishing between small cell lung carcinoma and non-small cell lung carcinoma, a clinically important differentiation.

Aims & Objective: To assess the diagnostic value & safety of Ultrasound Guided Transthoracic Fine Needle Aspiration Cytology examination in Bronchogenic Carcinoma.

Materials and Methods: Fine needle aspiration Cytology material from lung was obtained by Ultrasound Guided procedure from 31 suspected cases of malignant thoracic mass lesions on clinically & radiological work-up. Smear was made & stained with Hematoxylin & Eosin, Giemsa and Papanicoloua stain.

Results: In the present study out of 31 cases, lung carcinoma was diagnosed in 28 cases (90.32 %). Out of 28 patients, 27 cases (96.42 %) were diagnosed to have Non-small cell lung carcinoma category (NSCLC) which was further classified into Adenocarcinoma 9 cases (29.63%), Squamous cell carcinoma 8 cases (33.34%), Large Cell Carcinoma 3 cases (11.11%), Metastatic Carcinoma 2 cases (7.4%) and 5 cases (18.52 %) were unclassified. While only 1 case (3.58%) of Small Cell lung carcinoma category (SCLC) was diagnosed. In 2 cases inflammatory lesions were found and 1 case was inadequate for assessment. The diagnostic accuracy was 95%, sensitivity 96.55% and specificity 100% considering cytological criteria as the standard.

Conclusion: We concluded that Transthoracic Fine Needle aspiration Cytology with Ultrasound guided procedure is simple, safe & cost effective diagnostic technique in Bronchiogenic Carcinoma, with early diagnosis and minimal complications.

Key Words: Transthoracic Fine Needle Aspiration Cytology; Bronchiogenic Carcinoma; Non-Small Cell Lung Carcinoma; Small Cell Lung Carcinoma

Introduction

Bronchiogenic carcinoma is the most common malignancy in the world, accounting for 7% of all deaths in men and women. It is the leading cause of death in industrialised countries and also rising at alarming rates in developing countries.^[1] The diagnosis of Bronchiogenic carcinoma by cytologic methods is of historic interest because they were early manifestations of malignancy as diagnosed by examining the exfoliated cells. Donne and Walsh noted that exfoliated respiratory cells including cancer cells occurred in sputum as early as 1845. The first major series in patients in which the examination of sputum led to a diagnosis of lung cancer was by Hamplén in 1919.^[2] After several years of quiescence; pulmonary cytology enjoyed a period of rapid development in the 1970s and 1980s. During this time, fine needle aspiration was validated as an alternative to open lung biopsy and technical advance in radiologic technique as well as improvement in the design of bronchoscopes permitted the imaging of small lesions and guidance of fine needle.^[3]

Fine-needle aspiration cytology (FNAC) is a well-established method of diagnosing both neoplastic and

inflammatory conditions of the lungs.^[4] Together with other cytological methods of diagnosis of lung diseases, it has resulted in a decrease in the performance of procedures that are more invasive in nature. Transthoracic FNAC is regarded as the most effective of the cytological methods for diagnosing lung cancer, in particular peripherally-located lesions. It demonstrates high accuracy in distinguishing between small cell lung carcinoma and non-small cell lung carcinoma, a clinically important differentiation. It is cheap, can be repeated and the complication rate is low.^[5]

Thus this study was carried out to investigate the diagnostic value & safety of Ultra sound guided Transthoracic Lung Fine Needle Aspiration Cytology examination in Bronchogenic Carcinoma.

Materials and Methods

The present study was conducted at Pathology Department of S.S.G Hospital and Medical College, Baroda after getting approval from Ethical Committee. Ultrasound guided Fine needle Aspiration cytology of 31 patients with suspected thoracic mass lesions was done between December 2011 to November 2013. Suspicion

of malignancy was made depending on different clinical and radiological data. If the mass was peripheral or central with peripheral extension, we proceeded to Fine Needle Aspiration Cytology procedure under Ultrasound guidance. If the lesions were central or not accessible CT guided biopsy was advised.

A lumbar puncture needle of gauge 20 was used to collect the desired material and was passed through the marked site then Ultrasound machine probe confirmed that the needle was in the lesion and then the trocar was removed and 10 cc disposable syringe was attached and desired material was obtained by Fine Needle Aspiration Cytology procedure. Smear was made and material was stained with Hematoxylin & Eosin, Giemsa and Papanicoloua stain.

Results

In this study, we included 31 patients with suspected thoracic mass lesions who were hospitalized and examined in our hospital between December 2011 to November 2013. Among the total cases, male to female ratio was found to be 4:1 and mean age of the patients was 55.8±12.34 years. Maximum number of cases 18 (59.06 %) were in age group of 50-69 years. Non-Small Cell Lung Carcinoma (NSCLC) was found to be more common than Small Cell lung Carcinoma (SCLC). There were 27 (87.1%) cases of NSCLC and only 1 (3.22%) case of SCLC. General demographic findings of the study are summarised in Table 1.

Among the Non-small cell carcinoma category, Squamous cell carcinoma was found in 8 out of 27 cases, Adenocarcinoma in 9 cases, Large cell carcinoma in 3 cases, metastatic carcinoma in 2 cases and 5 cases were unclassified (Diagram 1). There was increased prevalence of Squamous cell carcinoma in males while Adenocarcinoma was found more common in females.

Table-1: Demographic description of the study

Characteristics		N	%
Age (Years)	Below 40	3	9.67
	40-49	5	16.12
	50-59	9	29.03
	60-69	9	29.03
	70 and above	5	16.12
Sex	Male	25	80.64
	Female	6	19.35
History of Smoking	Smokers	26	83.87
	Non-smokers	5	16.12
Lung Carcinoma	NSCLC	27	87.10
	SCLC	1	3.22
Sampling	Adequate	30	96.77
	Inadequate	1	3.22

Table-2: Results of Transthoracic FNAC regarding the diagnosis of Bronchogenic Carcinoma

Test result	Bronchogenic Carcinoma		
	Present	Absent	Total
Positive	28	0	28
Negative	1	2	3
total	29	2	31

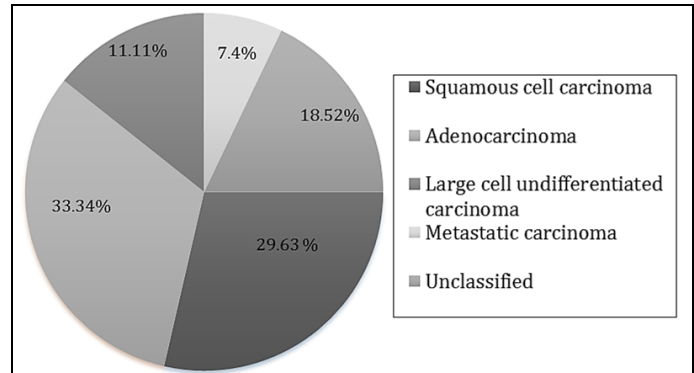


Figure-1: Malignant cell Type distribution among Non-small cell carcinoma category

Out of the total cases, True Positive results were 28 and none of them were false positive. Negative result was seen in three cases, out of which 2 cases were having infectious lesions and 1 case was inadequate.

According to Table-2 the Diagnostic sensitivity of USG Guided Transthoracic FNAC in Bronchiogenic Carcinoma was found to be 96.55% and the specificity 100% and the diagnostic accuracy was 96% considering cytological criteria as the standard.

The procedure was performed with very little complications, though the only complication developed due to the procedure was Pneumothorax which developed only in 1 cases (3.22 %) out of 31 cases.

Discussion

Transthoracic Fine needle aspiration cytology is a valuable method that can be used when sputum is unavailable, or the location of the lesion or clinical status of the patient is not suitable for bronchoscopic procedures. Compared with thoracotomy and open lung biopsy, it is a cheaper and an easier method and has a fairly low mortality rate.^[6] It has been used approximately for hundred years, has become a valuable diagnostic tool today by means of the improvements in guiding methods and cytopathologic evaluations.^[7] It does not require general Anaesthesia, is safe and can be repeated as needed. It provides results in a short period and can be applied on an outpatient basis and can be performed even in the patients under high risk (e.g. heart diseases).^[8]

The total number of cases in this study were 31 cases, out of which there were 25 males (80.64 %) and 6 females (19.35%). Lung carcinoma was diagnosed in 28 cases (90.32 %). Out of 28 patients, 27 cases (96.42 %) were diagnosed to have Non-small cell lung carcinoma category (NSCLC) which was further classified into Adenocarcinoma 9 cases (29.63%), Squamous cell carcinoma 8 cases (33.34%), Large Cell Carcinoma 3 cases (11.11%), Metastatic Carcinoma 2 cases (7.4%) and 5 cases (18.52 %) were unclassified. While only 1 case (3.58%) of Small Cell lung carcinoma category (SCLC) was diagnosed. Non-Small Cell Lung Carcinoma (NSCLC) was found to be more common than Small Cell lung Carcinoma (SCLC).

Majority of the cases in this study were 25 males (n=25 %) and 6 cases were females (19.35 %). The mean age of the patients was 55.8±12.34 years. These results are similar to findings of other studies. Hakan Solak et al^[8] conducted a study of 102 patients, 86 of them were male, 16 of them were female, and their mean age was 50±6.5 years. Md Quamrul Hassan^[1] also found similar results where average age of the patients was 60.14 years and male to female ratio was 5.5:1. Females were less because bronchiogenic carcinoma is less in females due to less smoking.

In this study, among 27 cases of Non-Small Cell Lung Carcinoma, Squamous cell carcinoma was found in 8 cases (29.63%). Adenocarcinoma was seen in 9 cases (33.34 %) and Large cell carcinoma was seen in only 3 case (11.11 %), Metastatic carcinoma in 2 cases (7.4%). The prevalence of squamous cell carcinoma and adenocarcinoma were similar (22%) in the study by Singh et al^[9] but our results showed higher prevalence of adenocarcinoma which is similar to the findings by K B Tan et al.^[5] Where they found Adenocarcinoma 37 (49.4%), Squamous cell carcinoma 12 (16.0%), Large cell lung carcinoma 2 (2.7%), Metastatic adenocarcinoma 3 (4.0%). In various literatures it is recorded that in the diagnosis of lung cancer, the sensitivity of Transthoracic FNAC technique is 80- 95%, and the specificity is 95-100%. In our study, the sensitivity was found to be 96.55%, the specificity 100% and, which is similar to the other studies by Singh et al^[9], Yaman et al^[10], Samurkaboulu B et al^[11] and Zhan et al^[12].

In the present study, the only complication developed was Pneumothorax, noted in only one case (3.1%). Pneumothorax was significantly lower than the 42.7%, 29%, 20.9% and 11.8% seen in the studies conducted by

Vanssonenberg et al^[13], Stanley et al^[14] Santambrogio et al^[15] and Singh et al^[9] respectively. This variability may be due to the differences in the definitions of significant complications and in the stringency in which they are reported. It was comparable similar to the 3.1%, 2.7% and 1.1% of Gouliamos et al^[16] and Gupta et al^[17].

Thus in this study Ultrasound Guided Transthoracic FNAC was done for the diagnosis of Bronchiogenic Carcinoma and was found to be an effective, safe and speedy and relatively cheap method and only complication developed was Pneumothorax. This study included 31 cases, though a large scale prospective or case controlled type study should be done to establish a statistical significance and correlation.

Conclusion

Transthoracic FNAC with Ultrasound guided procedure is an accurate and safe method for the diagnosis of localised lung lesions. Cytologically it can accurately distinguish SCLC from NSCLC because these two categories were the most relevant for directing therapy. It can be easily performed and is well-tolerated method with high diagnostic accuracy and low complication rate, and thus, obviates more invasive diagnostic procedures.

References

- Hussain MQ, Ahmad MSU, Rahman MZ, Ahmad S, Chaudary MAW. Clinicopathological profile of Bronchiogenic carcinoma in tertiary care hospital in Bangladesh. Journal of Chittagong Medical College Teachers' Association 2010; 21(1):45-49.
- Johnson WW, Frable WJ. Diagnostic respiratory cytopathology: Masson publishing, New York; 1979.
- Gronz H. cytological diagnosis of tumor of the chest. Acta Cytol 1973; 17: 139-148.
- Silverman JF. Inflammatory and neoplastic processes of the lung differential diagnosis and pitfalls in FNA biopsies. Diagn Cytopathol 1995; 13:448-62.
- Tan KB, Thamboo TP, Wang SC, Nilsson B, Rajwanshi A, Salto-Tellez M. Audit of Transthoracic Fine Needle Aspiration of the Lung: Cytological Subclassification of Bronchogenic Carcinomas and Diagnosis of Tuberculosis. Singapore Med J 2002;43(11):570-575.
- Tikkakoski T, Päivänsalo M, Siniluoto T, Hiltunen S, Typpö T, Jartti P, et al. Percutaneous ultrasound guided biopsy. Fine needle biopsy, cutting needle biopsy or both. Acta Radiologica 1993;34:30-34.
- Lovett JV, Manalo PB, Barcia TC, Bomberger RA, McGregor DB. Diagnosis of pulmonary masses by fine needle Aspiration. Am J Surg 1988; 156:441-5.
- Solak H, Oztas S, Aganoglu S, Tumer O, Hazar A, Kurutepe M. Diagnostic value of transthoracic fine needle aspiration biopsy in thoracic lesions. Turkish Respiratory Journal 2001;2(2):11-15.
- Sing JP, Garg L, Setia V. Compared tomography (CT) guided transthoracic needle aspiration cytology in difficult thoracic mass lesions - not approachable by USG. Indian J Radiol Imaging 2004;14:395-400.
- Yaman M, Kucukusta AR, Suzer K, Hacıhanefioglu U. The value of transthoracic needle aspiration for diagnosis of pulmonary lesions. Solunum Hastalıkları 1990; 1:11-6 (in Turkish).

11. Samurkaboulu B, Ozturk C. The diagnostic value of transthoracic needle biopsy in thoracic lesions using different methods. *Solunum Hastaliklari* 1991; 2:19-26 (in Turkish).
12. Ozhan MH, Tufan M, Aysan T. The diagnostic value of ultrasound guided fine needle aspiration biopsy in apically located lung masses. *Solunum* 1990; 15:517-522.
13. vanSonnenberg E, Casola G, Ho M, Neff CC, Varney RR, Wittich GR, et al. Difficult Thoracic Lesions: CT-guided biopsy Experience in 150 cases. *Radiology* 1988;167:457-61.
14. Stanley JH, Fish GD, Andriole JG, Gobien RP, Betsill WL, Laden SA, Schabel SI. Lung lesions: cytologic diagnosis by fine-needle biopsy. *Radiology* 1987;162(2):389-391.
15. Santambrogio L, Nosotti M, Bellaviti N, Pavoni G, Radice F, Caputo V. CT-guided fine needle aspiration cytology of solitary pulmonary nodules: a prospective, randomized study of immediate cytologic evaluation. *Chest* 1997;112:423-5.
16. Gouliamos AD, Giannopoulos DH, Panagi GM, Fletoridis NK, Deligeorgi-Politi HA, Vlahos. Computed tomography-guided fine needle aspiration of peripheral lung opacities: An initial diagnostic procedure? *Acta cytological* 2000;44(3):344-8.
17. Gupta S, Michael JW, Frank AM, Kamran A, Marshall EH. CT guided percutaneous needle biopsy of intrathoracic lesions by using the transternal approach: experience in 37 patients. *Radiology* 2002;222:57-62.

Cite this article as: Taviad DS, Hiriyur SP, Patel VA, Nikhra PC, Panchal AB. Diagnostic value of ultrasound guided transthoracic fine needle aspiration cytology in bronchogenic carcinoma. *Int J Med Sci Public Health* 2014;3:1007-1010.

Source of Support: Nil

Conflict of interest: None declared

IJMSPH